

Journal of Pharmacognosy and Phytotherapy

Volume 9 Number 2, February 2017

ISSN 2141-2502



*Academic
Journals*

ABOUT JPP

The **Journal of Pharmacognosy and Phytotherapy (JPP)** is published monthly (one volume per year) by Academic Journals.

The **Journal of Pharmacognosy and Phytotherapy (JPP)** is an open access journal that provides rapid publication (monthly) of articles in all areas of the subject such as ethnobotany, phytochemistry, ethnopharmacology, zoopharmacognosy, medical anthropology etc.

The Journal welcomes the submission of manuscripts that meet the general criteria of significance and scientific excellence. Papers will be published shortly after acceptance. All articles published in JPP are peer-reviewed.

Contact Us

Editorial Office: jpp@academicjournals.org

Help Desk: helpdesk@academicjournals.org

Website: <http://www.academicjournals.org/journal/JPP>

Submit manuscript online <http://ms.academicjournals.me/>

Editors

Dr. (Mrs) Banasri Hazra

*Research Scientist (U.G.C.)
Department of Pharmaceutical Technology
Jadavpur University
Calcutta - 700032
India*

Dr. Yuanxiong Deng

*Dept of Pharmaceutical Science
School of Medicine
Hunan Normal University
Tongzipo Road 371, Changsha 410013,
Hunan China*

Prof. Maha Aboul Ela

*Beirut Arab University, Faculty of Pharmacy, Beirut
Campus*

Dr. S. RAJESWARA REDDY

*Assistant Professor, Division of Animal Biotechnology
Department of Biotechnology, School of Herbal
Studies and Naturo Sciences,
Dravidian University, Kuppam – 517 425, A.P.
India*

Dr. Mekhfi Hassane

*University Mohammed the First, Faculty of Sciences,
Department of biology, Oujda, Morocco
Morocco*

Dr. Arun Kumar Tripathi

*Central Institute of Medicinal and Aromatic Plants
P.O. CIMAP, LUCKNOW-226015,
India*

Dr. Wesley Lyeverton Correia Ribeiro

*Universidade Estadual do Ceará, Faculdade
de Veterinária/Laboratório de Doenças
Parasitárias Av. Paranjana, 1700
Itaperi - Fortaleza
60740-903, CE - Brazil*

Dr. Maryam Sarwat

C/O A.M. Khan, House No. 195

Dr. Yong-Jiang Xu

*Saw Swee Hock School of Public Health,
National University of Singapore, Singapore.*

Prof. Dr. Adeolu Alex Adedapo

*Department of Veterinary Physiology,
Biochemistry and Pharmacology
University of Ibadan, Nigeria*

Dr. Joana S. Amaral

*Campus de Sta Apolónia,
Ap. 1134, 5301-857 Bragança,
Portugal*

Dr. Asad Ullah Khan

*Interdisciplinary Biotechnology UNIT
Aligarh Muslim University,
India*

Dr. Sunday Ene-ojo Atawodi

*Biochemistry Department
Ahmadu Bello University
Zaria, Nigeria*

Prof. Fukai Bao

*Department of Microbiology and Immunology,
Kunming Medical College
China*

Dr. Bhaskar C Behera

*Agharkar Research Institute
Dept. of Science & Technology,
Plant Science Division
India*

Prof. R. Balakrishna Bhat

*Walter Sisulu University
Department of Botany
Mthatha, South Africa*

Dr. Mohammad Nazrul Islam Bhuiyan

*BCSIR Laboratories;
Chittagong cantonment;
Chittagong-4220;
Bangladesh*

Dr. Baojun Bruce Xu

Beijing Normal University-Hong Kong Baptist
University United International College Zhuhai,
Guangdong Province,
China

Dr. Hamad H. Issa

Department of Physical Sciences,
School of natural Sciences,
The University of Dodoma,
Tanzania

Dr. Gagan Deep

Department of Pharmaceutical Sciences
School of Pharmacy,
University of Colorado Denver,
Colorado,
USA

Dr. Fengguo Xu

Dept of Epidemiology and Public Health,
Yong Loo Lin School of Medicine,
National University of Singapore,
Singapore

Dr. Haitao Lv

Medicine and Endocrinology,
Albert Einstein College of Medicine,
Yeshiva University,
USA

Hassane MEKHFI

University Mohammed the First,
Faculty of Sciences,
Department of biology,
Laboratory of Physiology and Ethnopharmacology,
Morocco

Dr. Subhash C. Mandal

Division of Pharmacognosy
Pharmacognosy and Phytotherapy Research
Laboratory,
Department of Pharmaceutical Technology,
Jadavpur University,
India.

Dr. Adibe Maxwell Ogochukwu

Clinical Pharmacy and Pharmacy Management,
Faculty of Pharmaceutical Sciences,
University of Nigeria, Nsukka
Enugu state,
Nigeria.

Dr. Odukoya, Olukemi Abiodun

Department of Pharmacognosy,
Faculty of Pharmacy
University of Lagos.
Nigeria.

Dr. Qinxue Richard Ding

Medical Center at Stanford University,
Palo Alto,
USA

Dr. Sulejman Redžić

Faculty of Science of the University of Sarajevo
33-35 Zmaja od Bosne St.,
Sarajevo,
Bosnia and Herzegovina

Dr. Michal Tomczyk

Medical University of Bialystok,
Faculty of Pharmacy,
Department of Pharmacognosy,
Poland

Dr. Ugur Çakilcioglu

Firat University,
Faculty of Science and Arts,
Department of Biology,
Elazig
Turkey

Prof. Samson Sibanda

National University of Science and Technology
Cnr Gwanda Road/Cecil Avenue,
Ascot, Bulawayo,
Zimbabwe

ARTICLE

Antioxidant and hepatoprotective effect of *Urtica* Dioica extract against N-nitroso methyl urea induced injuries in mice

19

El Ouar Ibtissem, Tartouga Maya Abir , Loucif Oumayma Rokeya and Naimi Dalila,

Full Length Research Paper

Antioxidant and hepatoprotective effect of *Urtica Dioica* extract against N-nitroso methyl urea induced injuries in mice

El Ouar Ibtissem^{1*}, Tartouga Maya Abir¹, Loucif Oumayma Rokeya¹ and Naimi Dalila^{1,2}¹Laboratory of Microbiological Engineering and Application, University Mentouri, Constantine, Algeria.²National High School of Biotechnology, Ali Mendjli, Constantine, Algeria.

Received 2 January, 2016; Accepted 12 April, 2016

The aim of this study is to investigate the antioxidant and protective effect of an aqueous extract from *Urtica dioica* on liver injuries, induced by one of the most potent dietary carcinogenic agents N- Nitroso methyl urea (NMU). Firstly, the free radical scavenging activity of *U. dioica* extract was assessed by measuring its capability to scavenge the radical 2,2-diphenyl-1-picrylhydrazyl (DPPH). Liver injury was induced in mice by intraperitoneal injection of NMU (50 mg/kg) while the aqueous extract of *U. dioica* was administered orally to the experimental animals. Haematoxylin/ Eosin based histology was performed to evaluate the histological changes in the liver. The result suggest that *U. dioica* extract contains high content of polyphenols and able to reduce DPPH radical. Furthermore, NMU treatment induces steatosis in mice liver, which is accompanied by inflammatory cell infiltration. Data show also that *U. dioica* extract can protect mice liver from NMU induced damage. These findings proved that *U. dioica* extract has an antioxidant activity and hepatoprotective effect against NMU induced injury.

Key words: N-nitrosomethylurea, *Urtica dioica*, antioxidant, liver.

INTRODUCTION

Cancer chemoprevention is defined as the use of natural, synthetic, biological or chemical agents to reverse, suppress, or prevent carcinogenic process and cancer progression (Saldanha and Tollefsbol, 2012). The success of several recent clinical trials in preventing cancer in high-risk populations suggests that chemoprevention is a rational and appealing strategy (Tsao et al., 2004).

Various dietary antioxidants have shown considerable promise as effective agents for cancer prevention by

reducing oxidative stress which has been implicated in the development of many diseases (Khan et al., 2008). Moreover, many studies have focused on the chemoprotective properties of fruits, vegetables and plants (Cochrane et al., 2008; Desai et al., 2008; Svejda et al., 2010; Paul et al., 2013).

Animal cancer models provide an invaluable resource for the identification of tumor markers and the development of therapeutic interventions, as well as enabling the study of the carcinogenic process

*Corresponding author. E-mail: ibtissem_elouar@yahoo.fr. Tel/Fax: + 213 31 81 11 84.

(Kelloff et al., 2005). Chemically induced tumors are of particular interest in terms of hosts–tumor interactions since they develop through carcinogenesis steps, developing as spontaneous arising cancer (Cekanova and Rathore, 2014). Among the most carcinogenic molecules used in animal models the nitroso compounds. These chemicals stimulate carcinogenesis in more than 40 animal species including higher primates and at a variety of sites and organs (Stuff et al., 2009).

N- Nitroso methyl urea (NMU) belongs to the N-nitroso group, it has been found in low quantities in our environment, our food and may also be formed from precursors in the human body (Mirvish, 1995, Shalini et al., 2012). It is a very potent resorptive carcinogen which can induce tumor formation in several organs like stomach, liver, oesophagus and mammary gland (Talcott et al. 1990)

The present study was designed to investigate; firstly the antioxidant activity of an aqueous extract from *U. dioica*, a wild growing plant in East of Algeria. Its aerial parts are used in Algerian traditional medicine for prevention and treatment of diabetes, rheumatism, eczema, anaemia, hair loss and as an antidiarrheal (Boudjelal, 2013). Then, the protective effect of *U. dioica* extract was evaluated on liver histology of NMU carcinogenesis mice model.

MATERIALS AND METHODS

Aqueous extract preparation

U. dioica leaves were dried at room temperature and coarsely ground before extraction. The dried powdered sample (0.36 g) was macerated for 24 h with 100 ml of distilled water. The supernatant was filtered and sterilized using 22 µm Millipore filter. The final concentration of the extract was 3.6 mg/ml.

Total phenolic content

The amount of total phenolic was determined using the Folin-Ciocalteu method (Gutfinger, 1981), the reaction mixture was composed of 0.5 mL of plant extract, 5.0 mL of distilled water, and 0.5 mL of the Folin-Ciocalteu reagent and 1.0 mL of saturated sodium carbonate solution was added. This mixture was shaken and allowed to stand for 1 h. The absorbance was measured at 725 nm. A calibration curve of gallic acid was prepared, and the results were expressed as mg/gallic acid equivalents (GAE) / ml. Data were expressed as mean ±SD from at least three separate experiments

DPPH assay

The free radical scavenging activity of *U. dioica* extract was measured by 1,1-diphenyl-2-picryl-hydrazil (DPPH) using the method described by Söhretoglu et al. (2012). Briefly 0.1 mM solution of DPPH in methanol was prepared; 1 ml of the solution was added to 3 ml of the extract at different concentrations (0.72, 1.44, 2.16, 2.88 and 3.6 mg/ml). The mixture was shaken vigorously and allowed to stand at room temperature for 30 min. Then the absorbance was measured at 517 nm. Lower absorbance

of the reaction mixture indicated higher free radical scavenging activity. The percent DPPH scavenging effect was calculated using the following equation:

$$\text{DPPH scavenging effect (\%)} = [(A_0 - A_1)/A_0] \times 100$$

Where A0 was the absorbance of the control reaction and A1 was the absorbance in the presence of the standard sample or extract.

The IC₅₀ value represented the concentration of the sample leading to 50% reduction in the initial DPPH concentration. Data were expressed as mean ±SD from at least three separate experiments

Experimental animals

Females *Mus musculus* mice (18-22 g) procured from Pasteur institute Algiers were housed in plastic cages at room temperature (22±1°C) under a 12 h light/dark cycle and provided with rodent chow and water. The animal studies were conducted after obtaining clearance from Institutional Animal Ethics Committee.

Experimental design

The mice were divided into four groups with 8 animals in each group and were given a dose regimen as given as follows:

Group I: Control animals were given normal saline solution (0,9%).
Group II: Animals received weekly a single dose of 50 mg/kg NMU diluted in 0,9% saline solution, then administrated intra peritoneally.
Group III: Animals received daily oral dose of 75 mg/kg of *U. dioica*.
Group IV: Animals received every week a single dose of NMU (50 mg/kg, diluted in 0.9% saline solution) administrated intra peritoneally. The treatment by NMU, in the two groups (II and IV), lasted for 3 consecutive weeks.

One day after the last injection of NMU, animals of the third group received daily dose of 75 mg/kg of *U. dioica* through oral gavage.

The treatment with the *U. dioica* extract, in the last two groups, was lasted for 15 and 30 consecutive days after NMU injection.

Histopathological studies

Liver tissue for histopathological analysis was fixed in 10% buffered formalin saline, processed by routine histology procedure and embedded in paraffin. Tissues sections were then stained with Hematoxylin/eosin and observed under light microscope OPTTECH OPTICAL TECHNOLOGY®.

All reagents were purchased from Sigma Aldrich, Algeria.

RESULTS

Total phenolic content

Total phenolic compounds, as determined by Folin Ciocalteu method, are reported as gallic acid equivalents (GAE) by reference to a standard curve ($y = 0.0091x + 0.0378$, $r^2 = 0.99$). Total phenolic content was in the range of 109.4 ± 2.05 GAE /ml which is the equivalent of 302.96 ± 5.70 GAE/g of dried powder (Table 1).

Table 1. Total phenolic content (as GAE/ml) and scavenging activity of DPPH ($\mu\text{g}/\text{ml}$) in *U. dioica* extract.

Parameter	Total polyphenols (GAE/ml)	IC50 value ($\mu\text{g}/\text{ml}$)
<i>Urtica dioica</i> aqueous extract	109.4 ± 2.05	8.73 ± 0.96
Ascorbic acid	-	6.13 ± 0.79

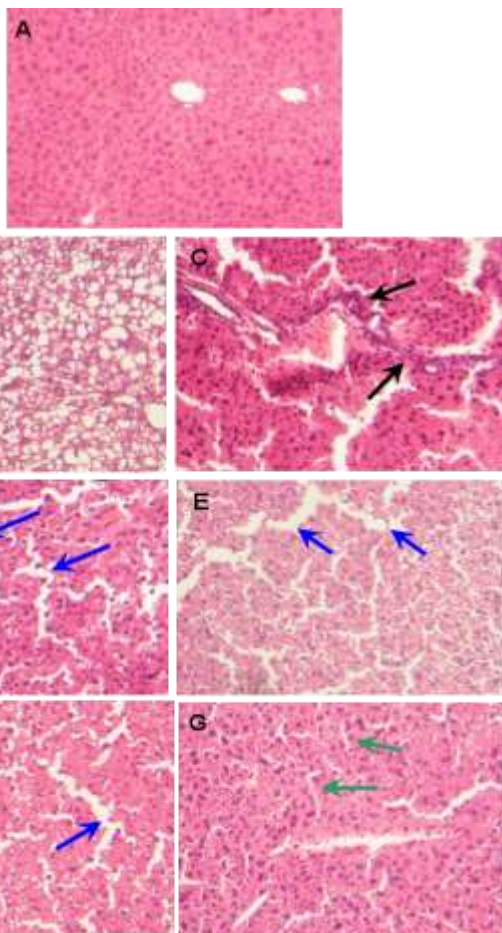


Plate 1. Photomicrographs of Hematoxylin and eosin stained sections of mice liver from different experimental groups (X100 magnification). Control group (A). Group 2, mice treated by intraperitoneal injection of NMU after 15 (B) and 30 (C) days. Group 3, mice treated by *U. dioica* extract after 15 (D) and 30 (E) days. Group 4, mice primed by NMU followed by *U. dioica* extract after 15(F) and 30 (G) days.

DPPH scavenging activity

The DPPH radical scavenging activity of *U. dioica* extract was increased by increasing the concentration of the sample extract. DPPH radical was scavenged by antioxidants through the donation of hydrogen, forming the reduced DPPH-H•. The color changes from purple to yellow after reduction, which can be quantified by its decrease of absorbance at wavelength 517 nm. The IC50

value (Table 1) of the extract was $8.73 \pm 0.96 \mu\text{g}/\text{ml}$ as opposed to that of ascorbic acid ($\text{IC}_{50} = 6.13 \pm 0.79 \mu\text{g}/\text{ml}$), a well-known antioxidant. Thus, the extract has a comparative antioxidant capacity to ascorbic acid.

Effect on liver histology

Plate 1 shows micrographs of the liver tissues from control and experimental animals. The liver section from the control group shows normal hepatocytes with preserved cytoplasm and central portal vein (Plate 1A). After 15 days, the tissue sections from NMU treated group show extensive fatty change with the apparition of steatosis (Plate 1B). The macrosteatosis was the most predominant form. A marked inflammatory cell infiltration (shown by black arrows in plate 1C) was observed after 30 days.

Histopathological examination of liver sections from *U. dioica* extract shows sinusoidal dilatation (shown by blue arrows in Plate 1D and E). In liver sections of mice primed by NMU followed by *U. dioica* extract we notice normal hepatocytes with no vacuolated cytoplasm and also no area of infiltration by inflammatory cells. With this treatment sinusoidal dilation was observed only after 15 days (shown by blue arrows in Plate 1F), after that sinusoid return to their natural form (shown by green arrows in Plate 1G). These features gave an indication of the protective effect of the extract.

DISCUSSION

In the present study, we assessed the antioxidant activity and studied the effect of an aqueous extract from *U. dioica* on the liver of NMU primed mice

This study showed that the extract has an antioxidant activity that seemed due to the presence of phenolic compounds in *U. dioica* leaves. Polyphenols are known to have antioxidant properties due to their ability of scavenging free radicals and active oxygen species such as singlet oxygen, free radicals and hydroxyl radicals. Antioxidant activity of *U. dioica* has been also reported by Gulcin et al. (2004) and Guder and Korkmaz (2012).

Free radicals are highly reactive species, capable in the nucleus, and in the membranes of cells of damaging biologically relevant molecules such as DNA, proteins, carbohydrates, and lipids (Young and Woodside, 2001). They have been associated with the pathogenesis of disorder like cancer diabetes and cardiovascular diseases (Ratnam et al., 2006).

The harmful factor used in the study was the mutagen NMU. Environmental factors comprising tobacco smoke and various nitrostable foods like cured meats, beer, fish and cheese constitute the principal sources of this compound (Stuff et al., 2009). Liver is the major site of detoxification and the primary target of drug exposure, in the body different toxins such as pharmaceuticals, herbals, foods and supplements may lead to hepatic damage (Lopez and Hendrickson, 2014).

Our results demonstrate that macrosteatosis (Plate 1B) is the main form of liver injury induced by NMU. This form is potentially reversible and often associated with necrotic inflammation (Ikonen, 2006; Marques et al., 2010). This report is in accordance with our results, where the carcinogen induces inflammation after 30 days of treatment (Plate 1C). Different effects of NMU have been reported, it stimulated liver carcinogenesis, hyperplasia of the hepatic cells, congestion of the central vein and dilation of sinusoids (Wang et al., 1993).

According to our findings *U. dioica* leaf extract applied for 15 and 30 days (Plate 1D and C), can cause a little damage in liver that is presented here by a sinusoidal dilatation. Other side effects of *U. dioica* leaves, like cell infiltration and sinusoidal congestion have reported by Gunes et al. (1999).

On the other hand, the extract given after NMU can restore the damages induced by the carcinogen (Plate 1F and G) and inhibits the carcinogenic process in the liver. Several experimental studies have investigated the role of *U. dioica* in the prevention and therapy of liver disease. However, hepatoprotective effect of *U. dioica* has been reported against CCL4 induced injuries (Kanter et al., 2005; Katakai et al., 2012) and acetaminophen toxicity (Juma et al., 2015).

Conclusion

In conclusion, the present study revealed that *U. dioica* extract contains high quantity of polyphenols and can act as a free radical scavenger. The results also suggested that the plant exhibited hepatoprotective effect against liver injuries induced by the chemical carcinogen NMU.

Conflict of interests

The authors hereby declare that no conflict of interest exists among them.

REFERENCES

- Boudjelal AC, Henchiri M, Sari D, Sarri N, Hendel A, Benkhaled G, Ruberto (2013). Herbalists and wild medicinal plants in M'sila (north Algeria): An ethnopharmacology survey. *J. Ethnopharmacol.* 148:395-409.
- Cekanova M, Rathore K (2014). Animal models and therapeutic molecular targets of cancer: utility and limitations. *Drug Des. Dev. Ther.* 8:1911-1922.
- Cochrane CB, Nair PK, Melnick SJ, Resek AP, Ramachandran C (2008). Anticancer effects of *Annona glabra* plant extracts in human leukemia cell lines. *Anticancer Res.* 28(2A):965-71.
- Desai AG, Qazi GN, Ganju RK, EL-Tamer, M, Singh J, Sexena AK, Yashbir SB, Taneja SC, Bhat H (2008). Medicinal plant and cancer chemoprevention. *Cur. Drug Metab.* 9(7):581-591.
- Guder A, Korkmaz H (2012). Evaluation of in-vitro antioxidant properties of hydroalcoholic solution extracts *Urtica dioica* L., *Malva neglecta* Wallr. and Their Mixture. *Iran J. Pharm. Res.* 11(3):913-923.
- Gulcin I, Kufrevioglu OI, Oktay M, Buyukokuroglu ME (2004). Antioxidant, antimicrobial, antiulcer and analgesic activities of nettle (*Urtica dioica* L.). *J. Ethnopharmacol.* 90:205-15.
- Gunes HV, Degirmenci I, Aydin M, Bozan B, Aral E, Tunalier Z, Ustuner C, Ercakar M, Baser KH, Basaran A (1999). The effects of *Rumex patientia* L. and *Urtica dioica* L. on some blood and urine parameters and liver and kidney histology in diabetic rats. *Tradit. J. Med. Sci.* 29:227-32.
- Gutfinger T (1981). Polyphenols in Olive Oils. *J. Am. Oil Chemists' Soc.* 58:966-968.
- Ikonen E (2006). Mechanisms for cellular cholesterol transport: Defects and human disease. *Physiol. Rev.* 86:1237-1261.
- Juma KK, David MN, Joseph JNN (2015). A Review of the Biochemical, Hematological and Histological Modulations in Acetaminophen Induced Hepatotoxicity and the Potential of *Urtica Dioica* in the Regeneration of the Liver. *J. Drug Metab. Toxicol.* 6:182.
- Kanter MV, Coskun O, Budancamanak M (2005). Hepatoprotective effects of *Nigella sativa* L and *Urtica dioica* L on lipid peroxidation, antioxidant enzyme systems and liver enzymes in carbon tetrachloride-treated rats. *World J. Gastroenterol.* 11(42):6684-6688.
- Katakai MS, Murugamani V, Rajkumari A, Mehra PS, Awasthi D, Yadav RS (2012). Antioxidant, Hepatoprotective, and Anthelmintic Activities of Methanol Extract of *Urtica dioica* L. Leaves. *Pharmaceut. Crops.* 3:38-46.
- Khan N, Afraq F, Mukhtar H (2008). Cancer chemoprevention through dietary antioxidants: progress and promise. *Antioxid. Redox Signal.* 10(3):475-510.
- Lopez AM, Hendrickson RG (2014). Toxin induced hepatic injury. *Emerg. Med Clin. North Am.* 32(1):103-125.
- Marques CM, Motta VF, Torres TS, Aquila M, Mandarin CA (2010). Beneficial effects of exercise training on insulin resistance and nonalcoholic fatty liver disease in high-fat fed C57BL/6 mice. *Br. J. Med. Biol. Res.* 43:467-475.
- Mirvish SS (1995). Role of N-nitroso compounds (NOC) and N-nitrosation in etiology of gastric, esophageal, nasopharyngeal and bladder cancer and contribution to cancer of known exposures to NOC. *Cancer Lett.* 93(1):17-48.
- Paul J, Gnanam R, Jayadeepa RM, Arul L (2013). Anti cancer activity on Graviola, an exciting medicinal plant extract vs various cancer cell lines and a detailed computational study on its potent anti-cancerous leads. *Cur. Top. Med. Chem.* 13(14):1666-73.
- Ratnam DV, Ankola DD, Bhardwaj V, Sahana DK, Kumar MN (2006). Role of antioxidants in prophylaxis and therapy: A pharmaceutical perspective. *J. Control Release* 113:189-207.
- Saldanha SN, Tollefsbol TO (2012). The role of nutraceuticals in chemoprevention and chemotherapy and their clinical outcomes. *J. Oncol. P* 23. Article ID 192464.
- Shalini V, Theeshan B, Arvind K (2012). N-methyl N-nitroso Urea induced altered DNA structure initiate hepatocarcinogenesis. *Preventive Med.* 54:S130-S136.
- Söhretoglu D, Sabuncuoglu S, Sebnem Harput U (2012). Evaluation of antioxidative, protective effect against H₂O₂ induced cytotoxicity and cytotoxic activities of three different *Quercus* species. *Food Chem. Toxicol.* 50:141-146.
- Stuff JE, Goh TG, Barrera SL, Bondy ML, Forman MR (2009). Construction of an N-nitroso database for assessing dietary intake. *J. Food Compos. Anal.* 22S:S42-S47.
- Svejda B, Aguiriano-Moser V, Sturm S, Höger H, Ingolic E, Siegl V, Stuppner R (2010). Anticancer Activity of Novel Plant Extracts from *Trailliaedoxa gracilis* (W. W. Smith & Forrest) in Human Carcinoid KRJ-I Cells. *Anticancer Res.* 30(1):55-64.
- Tsao AS, Kim ES, Hong WK. (2004). Chemoprevention of cancer. *CA. Cancer. J. Clin.* 54(3):150-180.

- Wang J, Zheng ZA, Zhang LS, Cao DM, Chen KZ, Lu D (1993).
An experimental study for early diagnostic features in fluorosis.
Fluoride 26:61-65.
- Young IS, Woodside JV (2001). Antioxidants in health and disease. J.
Clin. Pathol. 54:176-86.



Journal of Pharmacognosy and Phytotherapy

Related Journals Published by Academic Journals

- *African Journal of Pharmacy and Pharmacology*
- *Research in Pharmaceutical Biotechnology*
- *Medical Practice and Reviews*
- *Journal of Clinical Pathology and Forensic Medicine*
- *Journal of Medicinal Plant Research*

academicJournals